


Malunited Distal End Radius with Garden Spade Deformity and Distal Radioulnar Synostosis: A Case Report of a Quirky Wrist

ASWIN SUGUMARAN¹, DILIP KUMAR NAIDU², SABARI VAASAN LAKSHMIKANTHAN³, MADHAN RAJU⁴, KEVIN DHAS⁵

ABSTRACT

Distal end radius fractures are the most common type of wrist fracture and a significant complication associated with these injuries is malunion, which can lead to deformities that adversely affect the normal biomechanics of the wrist joint. Failing to address this malunion may result in chronic pain, a reduced range of motion and early-onset arthritis of the wrist joint. Therefore, it is essential to correct this malunion surgically, as doing so can greatly enhance functional outcomes for patients and improve their overall quality of life. Hereby authors report a rare case of a malunited distal end radius fracture with garden spade deformity and distal radioulnar synostosis. Upon presentation, the patient had a fixed wrist flexion deformity of 40° and a fixed pronation deformity of 20°. The patient was managed with corrective osteotomy of the malunited distal end radius, distal ulna excision and resection of the distal radioulnar synostosis. The preoperative measured volar tilt angle of 49.3° was corrected to 18.6°. At one year follow-up, the patient's QUICK DASH score improved from 50% (severe disability) to 11.4% (minimal disability) and the modified Mayo wrist score improved from a score of 35 (poor) to 80 (good).

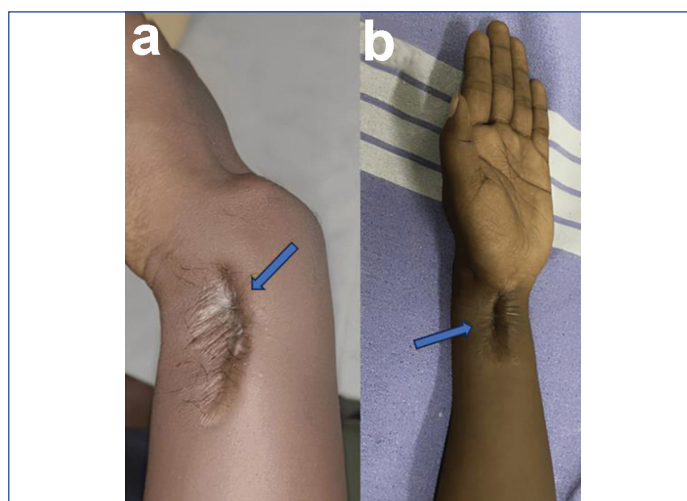
Keywords: Orthopaedic procedures, Osteotomy, Radius fractures, Wrist joint

CASE REPORT

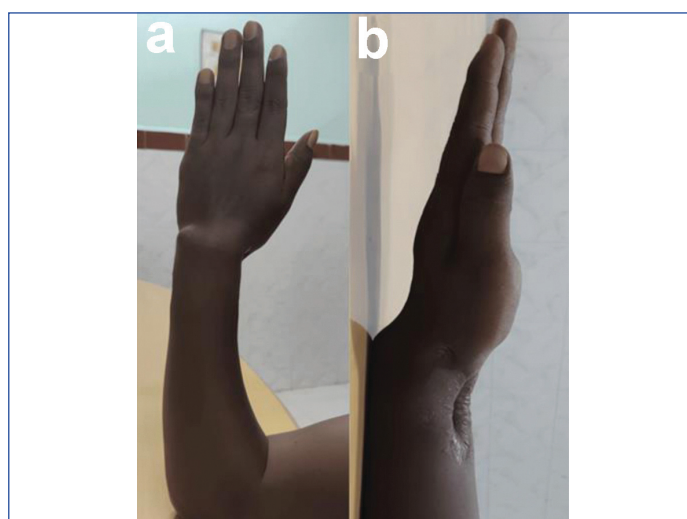
A 21-year-old male presented with complaints of deformity in the left wrist for the past seven years, intermittent left wrist pain and difficulty with forearm and wrist movements. He reported a history of falling from a tree seven years ago when he was 14 years old, at which time he was diagnosed with a compound fracture of the distal radius and distal ulna in the left wrist. He was initially treated with K-wire fixation for the distal radius and distal ulna fractures. Subsequently, the surgical site became infected, leading to wound debridement and K-wire removal, after which he was kept in a Plaster of Paris slab for immobilisation for two weeks.

Later, the patient underwent native bandaging treatment, which involved the application of three bandages at 15-day intervals. After the removal of the native bandaging, the patient complained of reduced range of motion in the wrist, intermittent pain in the left wrist and deformity in the left wrist, which had been progressively worsening over time. Upon presentation to our hospital, the examination findings revealed a healed scar over the distal ulnar and volar aspects of the distal forearm, with no active discharge [Table/Fig-1a,b], as well as a prominent ulnar styloid compared to the radial styloid [Table/Fig-2a]. The range of motion in the fingers and thumb was full. A fixed flexion deformity of the wrist of 40° [Table/Fig-2b] and a fixed pronation deformity of 20° were present [Table/Fig-3a]. There was a 4 cm shortening of the left upper limb [Table/Fig-3b]. There were no distal neurovascular deficits.

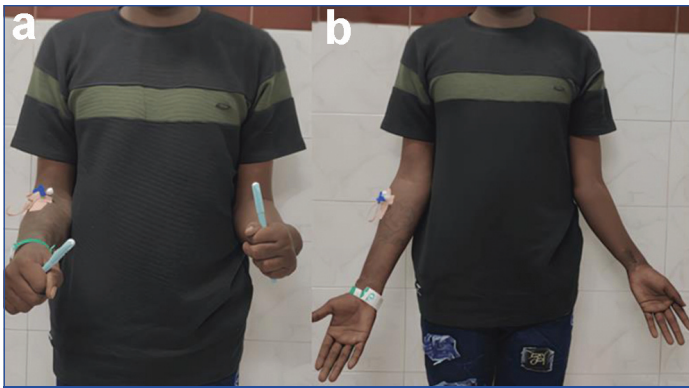
Radiological investigations were performed, including plain radiographs of the left wrist and left forearm [Table/Fig-4a-d] and a 3D Computed Tomography (CT) scan of the left wrist [Table/Fig-5a-d], which led to the diagnosis of a malunited distal radius fracture with a volar tilt deformity and distal radioulnar synostosis. The surgical management was planned based on the radiological parameters; the volar tilt angle measured 49.3° [Table/Fig-6] and there was positive ulnar variance. A dorsal wedge corrective osteotomy was planned to correct the volar tilt angle, as well as distal ulna resection for ulnar impingement and distal radioulnar synostosis.



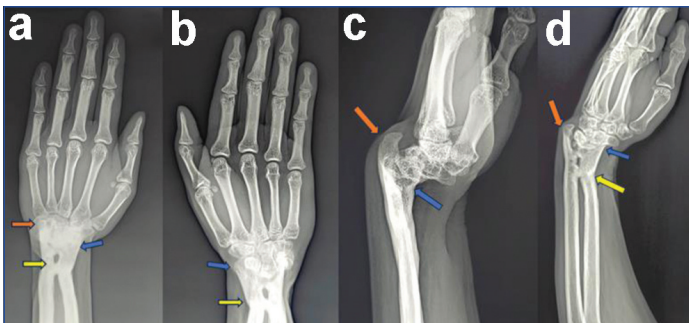
[Table/Fig-1]: Images showing healed scars over the left wrist and forearm. a) Distal ulnar aspect (blue arrow); b) Volar aspect (blue arrow).



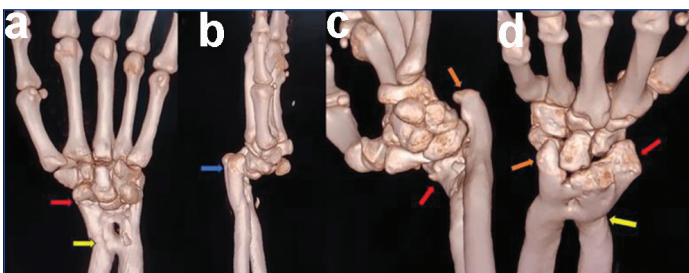
[Table/Fig-2]: Images showing the deformity over the left wrist. a) Prominent ulnar styloid compared with the radius styloid of the left wrist; b) Fixed flexion deformity of the left wrist (Garden Spade Deformity).



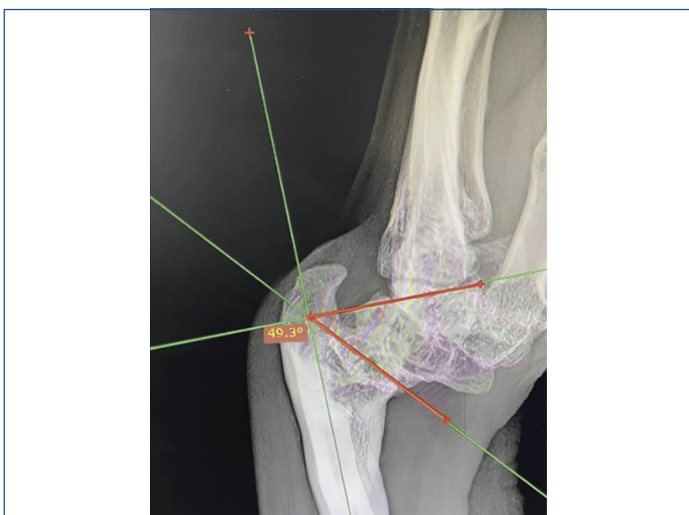[Table/Fig-3]: Images showing the pronation deformity of left forearm and left upper limb shortening. a) Fixed pronation deformity of 20°; b) Shortening of the left upper limb.



[Table/Fig-4]: Plain radiographs (X-rays) of the left wrist with forearm. a) Anteroposterior view showing positive ulnar variance (orange arrow) and distal radioulnar synostosis (yellow arrow); b) Posteroanterior view showing malunited distal end radius (blue arrow) and distal radioulnar synostosis (yellow arrow); c) Lateral view showing, prominent overriding of the distal ulna (orange arrow) and malunited distal end of radius with volar tilt (blue arrow); d) Oblique view showing, prominent overriding of the distal ulna (marked with orange arrow), distal radioulnar synostosis (yellow arrow) and malunited distal end of radius (blue arrow).



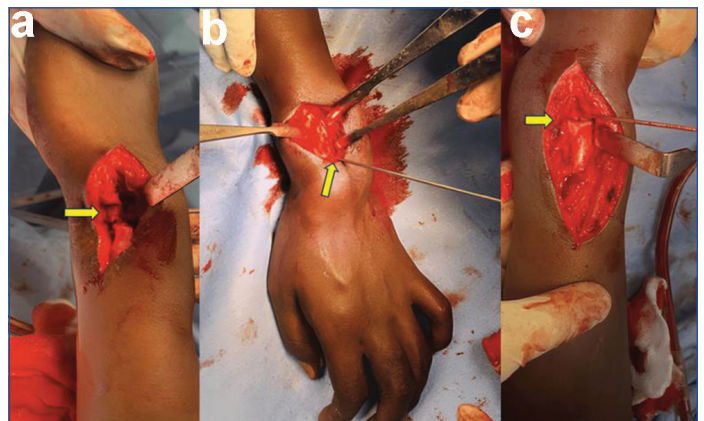
[Table/Fig-5]: 3D CT scan images of the left wrist. a) Anteroposterior view showing distal radioulnar synostosis (marked with yellow arrow) and malunited distal end radius (red arrow); b) Lateral view showing malunited distal end radius fracture (blue arrow); c) Medial view showing malunited distal end radius fracture (red arrow) and prominent distal ulna overriding (orange arrow); d) Superior view showing malunited distal end radius fracture (red arrow), prominent distal ulna overriding (marked with orange arrow) and distal radioulnar synostosis (marked with yellow arrow).



[Table/Fig-6]: X-ray lateral view of the left wrist with forearm showing volar tilt angle deformity of 49.3°.

Procedure

Following aseptic measures and a regional block, the patient was positioned in a supine position with their arm supported by an arm board. The surgical area was painted and draped. Using the dorsal approach, a midline skin incision measuring 10 cm was made over the dorsal surface between the radial and ulnar styloids. The skin and subcutaneous tissue were incised and retracted. Next, the extensor retinaculum was incised between the third and fourth extensor compartments of the wrist. The extensor tendons of these compartments were then secured and mobilised radially and ulnarly. Periosteal elevation was performed using a periosteal elevator. A distal ulnar resection was carried out at a level of 6 cm from the ulnar styloid for ulnar impingement, along with the excision of the distal radioulnar synostosis [Table/Fig-7a]. After securing a K-wire at the distal end of the radius as a guide [Table/Fig-7b], a bone saw was used to perform a closing wedge osteotomy at an angle of 30° on the extra-articular dorsal aspect of the radius. The osteotomised fragment was then removed and the angle was corrected by closing the wedge [Table/Fig-7c] and fixed with plating. The excised ulnar bone was used as a bone graft and fixed to the distal end of the radius with a screw to support the lunate carpal bone, compensating for the defect in the distal end of the radius.

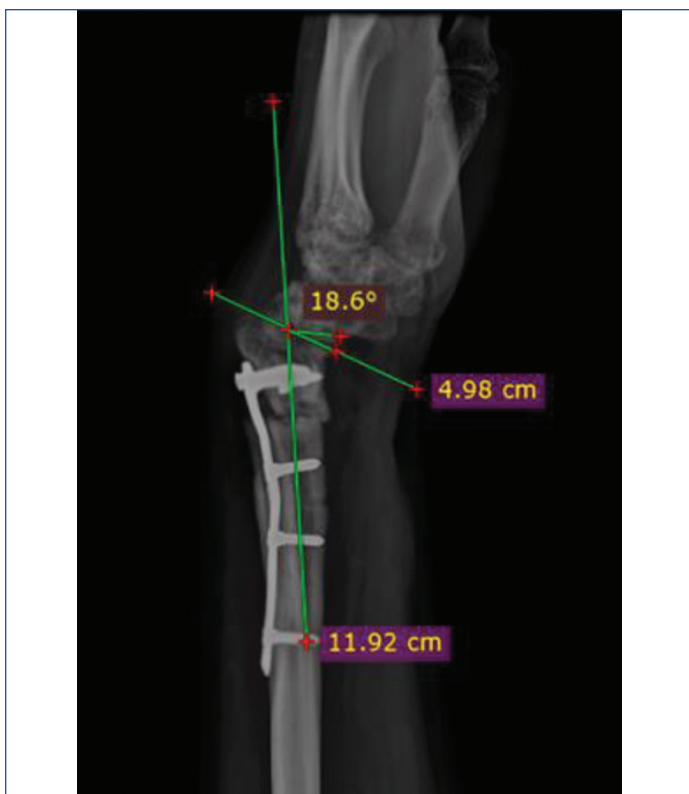

[Table/Fig-7]: Intraoperative images showing distal ulna resection and corrective osteotomy of distal end radius. a) Image showing distal ulna and distal radioulnar synostosis resection (marked with yellow arrow); b) Image showing using K-wire as a guide before doing osteotomy of distal end radius (marked with yellow arrow); c) Image showing corrected deformity of distal end radius after dorsal closed wedge osteotomy (marked with yellow arrow).

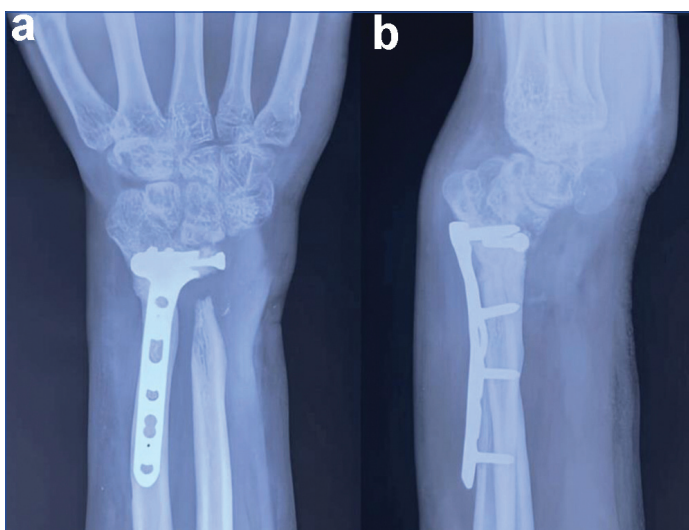
Postoperatively, the position of the implant was satisfactory [Table/Fig-8] and there were no neurological deficits. The left wrist was immobilised with a plaster of Paris slab for six weeks. After six weeks, the plaster slab was removed and range of motion exercises for the wrist, fingers, forearm and grip-strengthening exercises were initiated, continuing until 12 weeks. The postoperative X-ray of the left wrist revealed a corrected volar tilt angle, changing from 49.3° to 18.6° [Table/Fig-9a,b]. At the one-year follow-up, the patient exhibited an improved range of motion, with 50° of pronation and 90° of supination [Table/Fig-10a,b], as well as a correction of wrist deformity [Table/Fig-10c]. The Quick DASH score improved from preoperatively 50% (severe disability) to 29.5% (moderate disability) at the six-month follow-up and to 11.4% (minimal disability) at the one-year follow-up. The Modified Mayo wrist score improved from a preoperative score of 35 points (poor) to 70 points (fair) at the six-month follow-up and to 80 points (good) at the one-year follow-up.

DISCUSSION


Fractures of the distal radius are quite prevalent injuries. The literature indicates that malunion is the predominant consequence following distal radius fractures, occurring in approximately 23% of non surgically treated fractures and 11% of surgically treated fractures [1]. This condition leads to substantial functional impairment and higher morbidity rates. Typical signs of distal radius malunion include higher wrist pain, reduced grip strength and a limited range of motion [1].



[Table/Fig-8]: Postoperative X-ray of left wrist showing corrected volar tilt angle (18.6°).



[Table/Fig-9]: X-rays of the left wrist with forearm on follow-up showing united osteotomy site with implant in position. a) Anteroposterior view; b) Lateral view.



[Table/Fig-10]: Clinical images on follow-up showing good functional outcomes. a) Pronation of 50° (green arrow); b) Supination of 90° (green arrow); c) Clinical image showing corrected wrist deformity.

Experimental evidence consistently indicates that ulnar variance and volar tilt are the main factors determining the final outcome, while small variations in other radiographic parameters often have little impact on the outcome. Loss of radial inclination leads to an increase in stress at the radiolunate articulation [1]. Synostosis is defined as the osseous or fibrous fusion of the two forearm bones, which blocks pronation and supination [2].

Malunion of the distal radius can result in pain, stiffness of the wrist and fingers and a significant reduction in the range of motion and grip strength. In a distal radius fracture, a radial shortening of 2.5 cm results in the ulna bearing 42% of the axial load, which disrupts the alignment of the Distal Radioulnar Joint (DRUJ) and increases stress on the Triangular Fibrocartilage Complex (TFCC) [3]. Furthermore, the loss of normal palmar tilt accentuates the stress on the radioulnar ligaments. Shortening the radial length by 10 mm will decrease forearm pronation by 47% and supination by 29%. In cases of malunited volar tilt fracture of the distal end of the radius, the distal fragment exhibits an increased palmar tilt and a pronation deformity that promotes dorsal subluxation of the ulnar head. Such circumstances often lead to restrictions on active wrist extension and forearm supination. Therefore, prompt surgical intervention to rectify the malunion is of paramount importance [1].

Radius corrective osteotomy is a frequently performed yet challenging procedure for distal radius malunion. The closing-wedge osteotomy approach is an efficient reconstructive procedure for addressing extra-articular distal radial malunion. It is substantially better than the opening-wedge osteotomy procedure when it comes to the restoration of ulnar variance, the extension-flexion arc of wrist movement and the Mayo wrist score [4]. Achieving a complete restoration of radial length is not always attainable without an accompanying reduction in ulnar length [1,5]. Whenever issues regarding the restoration of radial length are anticipated, it is prudent to perform a concurrent ulnar shortening osteotomy alongside corrective osteotomy for malunion of the distal radius [6]. Darrach's excision of the distal ulna is a beneficial surgical procedure for patients experiencing post-traumatic stiffness or instability in the forearm, or significant disparity in radioulnar length during complicated reconstructive surgery. Primarily, the Darrach technique has resulted in substantial improvements in the range of forearm rotation movements [7].

The malunited distal end radius fracture usually presents with dorsal tilt; however, in present case, it exhibits a volar tilt deformity with distal radioulnar synostosis. Post-traumatic radioulnar synostosis and profound volar tilt deformity in a malunited distal end radius fracture are rare presentations, which had affected his daily activities. Thus, the patient after corrective osteotomy showed significant improvement in functional outcomes, with a Quick DASH score [8] of 11.4% (minimal disability) and a modified Mayo wrist score [9] of 80 points (good) at one-year follow-up.

CONCLUSION(S)

The most common consequence of a neglected distal end radius fracture is malunion with concomitant deformity, which leads to substantial problems with wrist and forearm function and impairs normal daily activities. Thus, prompt correction of this deformity through a corrective osteotomy procedure can restore wrist and forearm function while minimising cosmetic issues. In present case, a unique presentation of a volar tilt deformity (Garden spade deformity), resulting from a neglected malunited distal end radius fracture with distal radioulnar synostosis, was successfully managed with a dorsal wedge corrective osteotomy of the radius and distal ulna, along with resection of the radioulnar synostosis, culminating in good functional outcomes for carrying out daily activities.

REFERENCES

- [1] Dutta KK, Dutta A, Daolagupu AK, Mudgal A. A study on functional and radiological outcome after corrective osteotomy and volar locked plate fixation for extra-articular malunion of distal radius. *Int J Orthop Sci.* 2017;3(2):519-25. Doi: 10.22271/ortho.2017.v3.i2e.49.
- [2] Dohn P, Khiami F, Rolland E, Goubier JN. Adult post-traumatic radioulnar synostosis. *Orthop Traumatol Surg Res.* 2012;98(6):709-14. Doi: 10.1016/j.otsr.2012.04.018.
- [3] Liu TY, Yang CY. Management of extra-articular and intra-articular distal radius malunion. *Life.* 2024;14(9):1177. Doi: 10.3390/life14091177.
- [4] Wada T, Tatebe M, Ozasa Y, Sato O, Sonoda T, Hirata H, et al. Clinical outcomes of corrective osteotomy for distal radial malunion: A review of opening and closing-wedge techniques. *J Bone Joint Surg Am.* 2011;93(17):1619-26. Doi: 10.2106/JBJS.J.00500.

- [5] Brown JN, Bell MJ. Distal radial osteotomy for malunion of wrist fractures in young patients. *J Hand Surg Br.* 1994;19(5):589-93. Doi: 10.1016/0266-7681(94)90121-X.
- [6] Oskam J, Bongers KM, Karthaus AJ, Frima AJ, Klasen HJ. Corrective osteotomy for malunion of the distal radius: The effect of concomitant ulnar shortening osteotomy. *Arch Orthop Trauma Surg.* 1996;115:219-22. Doi: 10.1007/BF00434558.
- [7] Wijffels MM, Brink PR, Schipper IB. Clinical and non-clinical aspects of distal radioulnar joint instability. *Open Orthop J.* 2012;6:204-10. Doi: 10.2174/1874325001206010204.
- [8] Beaton DE, Wright JG, Katz JN, Upper Extremity Collaborative Group. Development of the QuickDASH: Comparison of three item-reduction approaches. *J Bone Joint Surg Am.* 2005;87(5):1038-46. Doi: 10.2106/JBJS.D.02060.
- [9] Slutsky DJ. Outcomes assessment in wrist surgery. *J Wrist Surg.* 2013;2(1):01-04. Doi: 10.1055/s-0033-1333892.

PARTICULARS OF CONTRIBUTORS:

1. Junior Resident, Department of Orthopaedics, SRM Medical College Hospital and Research Centre, SRM Institute of Science and Technology (SRMIST), Chengalpattu, Tamil Nadu, India.
2. Professor, Department of Orthopaedics, SRM Medical College Hospital and Research Centre, SRM Institute of Science and Technology (SRMIST), Chengalpattu, Tamil Nadu, India.
3. Associate Professor, Department of Orthopaedics, SRM Medical College Hospital and Research Centre, SRM Institute of Science and Technology (SRMIST), Chengalpattu, Tamil Nadu, India.
4. Senior Resident, Department of Orthopaedics, SRM Medical College Hospital and Research Centre, SRM Institute of Science and Technology (SRMIST), Chengalpattu, Tamil Nadu, India.
5. Assistant Professor, Department of Orthopaedics, SRM Medical College Hospital and Research Centre, SRM Institute of Science and Technology (SRMIST), Chengalpattu, Tamil Nadu, India.

NAME, ADDRESS, E-MAIL ID OF THE CORRESPONDING AUTHOR:

Dr. Aswin Sugumaran,
Junior Resident, Department of Orthopaedics, SRM Medical College Hospital and Research Centre, SRM Institute of Science and Technology (SRMIST), Chengalpattu-603211, Tamil Nadu, India.
E-mail: as1446@srmist.edu.in

PLAGIARISM CHECKING METHODS: [Jain H et al.]

- Plagiarism X-checker: Oct 18, 2024
- Manual Googling: Dec 28, 2024
- iThenticate Software: Jan 01, 2025 (17%)

ETYMOLOGY: Author Origin**EMENDATIONS:** 6**AUTHOR DECLARATION:**

- Financial or Other Competing Interests: None
- Was informed consent obtained from the subjects involved in the study? Yes
- For any images presented appropriate consent has been obtained from the subjects. Yes

Date of Submission: **Oct 10, 2024**Date of Peer Review: **Dec 24, 2024**Date of Acceptance: **Jan 03, 2025**Date of Publishing: **Feb 01, 2025**